



Arthroscopic Bankart Repair With Remplissage in Anterior Shoulder Instability Results in Fewer Redislocations Than Bankart Repair Alone at Medium-term Follow-up of a Randomized Controlled Trial

Jarret M. Woodmass,^{*†‡} MD, Sheila McRae,^{‡§} PhD, Peter Lapner,^{||} MD , Ivan Kamikovski,[†] MD, Benjamin Jong,[†] MD, Jason Old,^{†‡} MD, Jonathan Marsh,^{†‡} MD , Jamie Dubberley,^{†‡} MD, Greg Stranges,^{†‡} MD, Treney M. Sasyniuk,[§] MSc, and Peter B. MacDonald,^{†‡} MD
Investigation performed at Pan Am Clinic, Winnipeg, Manitoba, Canada; and University of Ottawa, Ottawa, Ontario, Canada

Background: A multicenter, double-blinded randomized controlled trial comparing isolated Bankart repair (NO REMP) to Bankart repair with remplissage (REMP) reported benefits of remplissage in reducing recurrent instability at 2 years postoperative. The ongoing benefits beyond this time point are yet to be explored.

Purpose: To (1) compare medium-term (3 to 9 years) outcomes of these previously randomized patients undergoing isolated Bankart repair (NO REMP) or Bankart repair with remplissage (REMP) to manage recurrent anterior glenohumeral instability; (2) examine the failure rate, overall recurrent instability, and reoperation rate.

Study Design: Randomized controlled trial; Level of evidence, 1.

Methods: Recruitment and randomization for the original randomized trial occurred between 2011 and 2017. Patients ≥ 14 years diagnosed with recurrent traumatic anterior shoulder instability with an engaging Hill-Sachs defect of any size were included. Those with a glenoid defect $>15\%$ were excluded. In 2020, participants were contacted by telephone and asked standardized questions regarding ensuing instances of subluxation, dislocation, or reoperation on their study shoulder. “Failure” was defined as a redislocation, and “overall recurrent instability” was described as a redislocation or ≥ 2 subluxations. Descriptive statistics, relative risk, and Kaplan-Meier survival curve analyses were performed.

Results: A total of 108 participants were randomized, of whom 50 in the NO REMP group and 52 in the REMP group were included in the analyses in the original study. The mean number of months from surgery to the final follow-up was 49.3 and 53.8 months for the NO REMP and REMP groups, respectively. Failure rates were 22% (11/50) in the NO REMP group versus 8% (4/52) in the REMP group. Rates of overall recurrent instability were 30% (15/50) in the NO REMP group versus 10% (5/52) in the REMP group. Survival curves were significantly different, favoring REMP in both scenarios.

Conclusion: For the treatment of traumatic recurrent anterior shoulder instability with a Hill-Sachs lesion and subcritical glenoid bone loss ($<15\%$), a significantly lower rate of overall postoperative recurrent instability was observed with arthroscopic Bankart repair and remplissage than with isolated Bankart repair at a medium-term follow-up (mean of 4 years). Patients who did not receive a remplissage experienced a failure (redislocated) earlier and had a higher rate of revision/reoperation than those who received a concomitant remplissage.

Registration: NCT01324531 (ClinicalTrials.gov identifier).

Keywords: anterior shoulder instability; arthroscopy; Bankart repair; medium-term remplissage

Arthroscopic repair of the capsulolabral complex has become the most common intervention for treating

traumatic recurrent anterior glenohumeral instability.^{18,26} Younger age, participation in contact or overhead sports, hyperlaxity, glenoid bone loss, and/or a Hill-Sachs lesion place patients at increased risk for a recurrent dislocation after repair.²⁵ The Hill-Sachs lesion has been identified as a common pathology, affecting 67% to 93% of patients,^{32,35} and the size and location of the Hill-Sachs lesion is significantly associated with recurrent instability.^{8,9}

Burkhart and De Beer⁶ highlighted the importance of bony defects in recurrent shoulder instability after soft tissue procedures by introducing the concept of “engaging” Hill-Sachs lesions. The concept of glenoid track³⁴ and the evolution of on-track/off-track lesions¹⁰ further enhanced the role of bone defects in the failure of shoulder stabilization procedures. Purchase et al²⁴ described the remplissage technique whereby the infraspinatus tendon and posterior capsule are transposed into the Hill-Sachs deformity using an arthroscopic approach. This technique was thought to prevent the “engagement” phenomenon by making the Hill-Sachs defect extra-articular.

Isolated Bankart repair has been criticized for its decreasing effectiveness over time, resulting in high rates of recurrent glenohumeral instability at long-term follow-up.^{31,36} Previous case series have suggested sustainable long-term outcomes in terms of recurrence rate without significant changes in shoulder range of motion for remplissage in addition to Bankart repair.^{5,33} Thus, remplissage has demonstrated some early promise; nonetheless, its effectiveness in preventing late failures requires further corroboration.

We previously conducted a multicenter, double-blinded, randomized controlled trial comparing arthroscopic Bankart repair with and without remplissage in patients with a Hill-Sachs lesion and subcritical glenoid bone loss.²¹ The key finding of the study was that the rate of postoperative recurrent instability was significantly reduced in patients undergoing arthroscopic Bankart repair with remplissage compared with those who underwent isolated arthroscopic Bankart repair at 24 months postoperative. In addition, no differences were found in any subjective outcomes at any time point (3, 6, 12, and 24 months postoperative), specifically, the Western Ontario Shoulder Instability score, the American Shoulder and Elbow score, or the Simple Shoulder Test. The purpose of the present study was to compare the medium-term outcomes of the patients randomized to isolated arthroscopic Bankart repair (NO REMP) or Bankart repair with remplissage (REMP) in the previous study. The rate of overall postoperative recurrent instability and instances of reoperation were examined. It was hypothesized that the REMP group would continue to have significantly lower rates of postoperative instability and reoperation when compared with the NO REMP group at a medium-term follow-up.

METHODS

This was a medium-term follow-up study of a double-blinded, randomized clinical trial with two 1 to 1 parallel groups conducted at 2 sites with recruitment undertaken between 2011 and 2017 (full methodology of the original trial is described in a previous article²¹). Ethics approval was granted from institutional review boards as follows: University of Manitoba Biomedical Research Ethics Board (B2010:166) and the Ottawa Health Science Network—Research Ethics Board 2011428-01H. The study was registered with clinicaltrials.gov NCT01324531. Six upper-extremity fellowship-trained surgeons (P.L., J.O., J.M., J.D., G.S., P.M.) contributed patients who provided informed consent to treatment. The inclusion criteria were patients ≥ 14 years diagnosed with recurrent traumatic anterior shoulder instability with an engaging Hill-Sachs defect of any size confirmed intraoperatively or preoperatively on magnetic resonance imaging (MRI) or computed tomography (CT) in which the patient could benefit from an arthroscopic Bankart repair with or without an arthroscopic infraspinatus remplissage. The exclusion criteria were as follows: a glenoid defect of $>15\%$ of the anteroposterior diameter of the glenoid; multidirectional instability or laxity; significant shoulder comorbidities, including osteoarthritis and previous surgery on the affected shoulder; active joint or systemic infection; significant muscle paralysis; rotator cuff tear arthropathy; Charcot arthropathy; significant medical comorbidity that could alter the effectiveness of the surgical intervention (eg, cervical radiculopathy, polymyalgia rheumatica); major medical illness (life expectancy 1 year or unacceptably high operative risk); inability to speak or read English/French; a psychiatric illness that precludes informed consent; or unwilling to be followed for 2 years.²¹

Patient positioning was in the lateral decubitus or beach-chair position and was based on surgeon preference. Details of the surgical technique of performing the remplissage are provided in the original study.²¹ To summarize, the remplissage was performed using an anterosuperior viewing portal and a posterolateral working portal at the lateral aspect of the convexity of the humeral head over the Hill-Sachs lesion. If the Hill-Sachs lesion was found to be engaging and the patient was randomized to remplissage, the surface of the lesion was debried to stimulate punctate bleeding, followed by placement of 2 anchors

*Address correspondence to Jarret M. Woodmass, MD, Pan Am Clinic, 75 Poseidon Bay, Winnipeg MB R3M 3E4, Canada (email: jwoodmass@panamclinic.com).

[†]Orthopaedic Surgery, Pan Am Clinic, Winnipeg, Manitoba, Canada.

[‡]Department of Surgery, Section of Orthopaedics, University of Manitoba, Winnipeg, Manitoba, Canada.

[§]Pan Am Clinic Foundation, Winnipeg, Manitoba, Canada.

^{||}The Ottawa Hospital, Ottawa, Ottawa, Canada.

Submitted October 16, 2023; accepted March 26, 2024.

One or more of the authors has declared the following potential conflict of interest or source of funding: The Pan Am Clinic Foundation is supported by Conmed, Arthrex, Ossur, Smith & Nephew, Stryker, and Zimmer Biomet. J.M.W. has received consulting fees from Smither & Nephew and Stryker. P.B.M. has received consulting fees from Conmed and Arthrex. AOSSM checks author disclosures against the Open Payments Database (OPD). AOSSM has not conducted an independent investigation on the OPD and disclaims any liability or responsibility relating thereto.

with sutures passed through the infraspinatus tendon. Various techniques were utilized to perform the remplissage based on surgeon preference—including knotless and knotted constructs, as well as both direct and blind techniques. Bankart repairs were completed at the surgeon's discretion before or after the remplissage. Three anchors were typically used to perform the repair with sutures incorporating the anterior labrum and associated capsular ligaments. At the completion of the procedure, the sutures were tied or tensioned based on standard versus knotless anchors. Postoperative care, immobilization, and rehabilitation were identical for both groups. Randomization was performed on the day of surgery using a telephone-based randomization system, and patients were allocated to either (1) NO REMP or (2) REMP. To characterize the study population at the time of the original study, Hill-Sachs lesions were measured post hoc by 2 surgeons (P.L., P.M.), 1 at each center, using preoperative MRI axial views (measurements on 3 patients were undertaken based on CT scans). The depth (mm) was measured from the perimeter of a best-fit circle to the deepest part of the lesion, the width (mm) was measured through the widest portion of the lesion, and the humeral head diameter (mm) was measured across the best-fit circle. The percentage of the humeral head bone loss was then calculated as Hill-Sachs depth/humeral head diameter \times 100 and reported as a percentage.^{19,21} Glenoid bone loss was measured using the best-fit circle method during the initial study.^{21,30} The amount of glenoid bone loss was not documented beyond the study eligibility requirements²¹ (<15%).

Study visits in the original trial included preoperative, 2 weeks, 3, 6, 12, and 24 months postoperative. To capture medium-term follow-ups (ie, >24 months), a letter was mailed to all participants in the first quarter of 2020 informing them a researcher would contact them by telephone for an additional study-related follow-up. A researcher blinded to group allocation attempted to reach the participants by phone (I.K., B.J.). When reached, the participant was asked a series of standardized questions regarding ensuing instances of subluxation or dislocation on the study shoulder after the index surgery. Specifically, they were asked, "Since the initial surgery, has your study shoulder subluxed at all? This means that it feels like it is going to dislocate but does not quite completely go out," and "Since the surgery, has your study shoulder dislocated at all? This means that it feels like it has gone out of the joint completely." Patients were asked to provide the approximate dates of these occurrences if possible. They were also asked whether they had undergone any additional surgeries on either shoulder since their last follow-up. No clinical verification of dislocation or subluxation was conducted in this study. A chart review was conducted to confirm details if any further injuries or surgeries were reported.

Data Analysis

The sample size for this trial was determined based on calculations performed in the original study, with an attempt to reach all patients again for a medium-term follow-

up. Descriptive statistics were generated for all variables. Reinjury was reported based on previous definitions of "failure" and "overall recurrent instability." Failure was defined as the occurrence of a redislocation on the study shoulder, which was described to the patient as the shoulder going out of joint completely. Overall recurrent instability was defined as the participant reporting either a redislocation or ≥ 2 occurrences of subluxation >1 year postoperative. Because the outcomes for this study were based primarily on patient self-report, it was thought that redislocation was a more explicit and easily distinguishable occurrence and, thus, represented failure of the surgery. However, it was thought there was also value in capturing an outcome that reflected patient-reported sensations of less explicit occurrences of instability by adding instances of repeated subluxation to reporting overall recurrent instability. It is not uncommon for patients to report experiencing a sense of instability early postoperative that reflects fear or apprehension during the initiation of motion and the progression of activity rather than true instability. Thus, a threshold of 1 year postoperative was specified to distinguish these responses, as most patients have returned or attempted to return to full function and activities by that time.

All analyses were undertaken based on intention-to-treat, whereby patient data were analyzed based on the group to which they were originally allocated. Relative risk with 95% CIs was calculated for failure and overall recurrent instability. A Kaplan-Meier survival analysis was performed, and a log-rank test was run to determine whether there were differences in survival distributions between No REMP and REMP. For the time factor in the survival analysis, the number of months from the time of surgery to outcome (either failure or no failure) was based on the date of the medium-term follow-up phone call, or from the date of the last reported outcome based on clinical or study follow-ups, whichever was the greatest. Consistent with the analysis in the original study, comparisons between groups on redislocation and overall recurrent instability in those flagged as high-risk for redislocation based on the Hill-Sachs size were also conducted. High risk was defined as having a Hill-Sachs $\geq 15\%$ of the humeral head diameter or a width ≥ 2 cm.^{11,28} Statistical significance was set as $P < .05$. All analyses were conducted using SPSS Version 27 (IBM).

RESULTS

A total of 108 participants were randomized in the original study with comparable demographic characteristics in each group ($n = 54$ per group) (Table 1); 50 in the No REMP group and 52 in the REMP group were included in the original study's analysis.²¹ Figure 1 presents the CONSORT (Consolidated Standards of Reporting Trials) flow diagram of patients through the original and present study. For the present medium-term study, no information beyond the original endpoint of 2 years was available for 14 of 50 participants in the NO REMP group and 10 of 52 in the REMP group; however, all participants were included

TABLE 1
Characteristics of Patients by Group at the Time of Initial Randomization^a

	NO REMP	REMP
Number of randomized patients, n	54	54
Sex, male/female, n (%)	48 (89) / 6 (11)	46 (85) / 8 (15)
Age, y, mean (SD, min-max)	27.8 (8.8, 15.4-55.2)	27.3 (8.8, 14.4-53.6)
BMI, mean (SD)	25.9 (3.8)	25.5 (3.3)
Contact or high-risk sport participation, ^b n (%)	23 (46)	19 (37)
Preoperative dislocations, mean (SD)	12 (13.4)	10.3 (9.5)
Humeral bone loss, % mean (SD)	15.8 (4.3)	15.1 (4.2)

^aBMI, body mass index; REMP, Bankart repair with remplissage.

^bHockey, football, rugby.

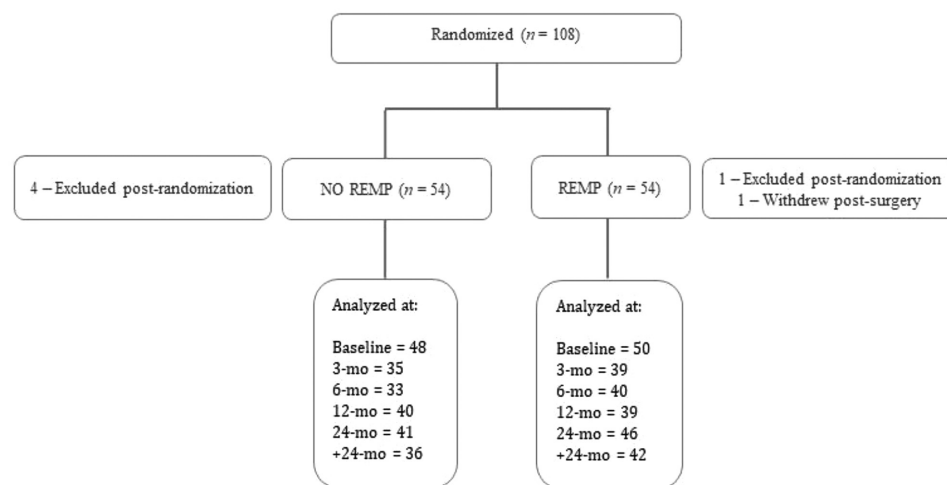


Figure 1. CONSORT (Consolidated Standards of Reporting Trials) flow diagram. REMP, Bankart repair with remplissage.

in the survival analysis utilizing the number of months to their last known outcome (eg, 3-month study visit). The mean (SD) number of months from surgery to the final follow-up was 49.3 (27.1) for the NO REMP group and 53.8 (29) for the REMP group.

Also, 4 of 52 participants (7.7%) in the REMP group experienced failure (redislocated) at a mean of 23.8 (18.1) months postoperative compared with 11 of 50 (22%) in the NO REMP group who failed earlier than the REMP group at a mean of 16.5 (11.3) months. The relative risk of failure in the REMP group relative to the NO REMP group was 0.350 (0.119-1.026). The survival curves were significantly different, favoring REMP ($\chi^2 = 4.412$; $P = .036$) (Figure 2).

Also, 5 of 52 participants (9.6%) in the REMP group experienced overall postoperative recurrent instability at a mean of 24 (15.7) months postoperative, compared with 15 of 50 (30%) in the NO REMP group at a mean of 19.5 (11.2) months. The relative risk of overall recurrent instability in the REMP group relative to the NO REMP group was 0.321 (0.126-0.816), and the survival curves were significantly different, favoring REMP ($\chi^2 = 6.958$; $P = .008$) (Figure 3).

With respect to subset analyses, 41 of 50 (82%) and 42 of 52 (80.8%) patients in the NO REMP and REMP groups, respectively, were identified in the original trial as high risk for reinjury based on the Hill-Sachs size. Of these, 11 of 41 (27%) in the NO REMP group and 4 of 42 (10%) in the REMP group experienced failure (redislocated) at the medium-term follow-up, and this difference was statistically significant ($P = .040$) (Table 2). Furthermore, of those patients considered high risk, 13 of 41 (31.7%) in the NO REMP group and 4 of 42 (9.5%) patients in the REMP group experienced an episode of overall recurrent instability (dislocation or subluxation), which was also statistically significant between groups ($P = .012$). Regarding the subset of patients who played contact sports, 7 of 23 (30%) and 1 of 19 (5.3%) patients in the NO REMP and REMP groups, respectively, experienced postoperative failure (redislocation).

A greater number of revision surgeries and reoperations were observed in the NO REMP versus REMP group (8 and 2, respectively). The most frequent revision surgery was a Latarjet procedure. Patient characteristics of those who experienced a failure and/or overall recurrent instability, along with the treatment received, are outlined in Table 2.

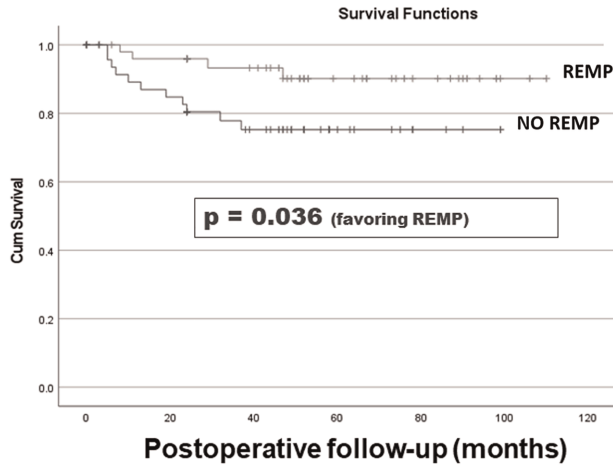


Figure 2. The survival curve for patients undergoing Bankart and remplissage or Bankart repair only comparing the time to dislocation. REMP, Bankart repair with remplissage.

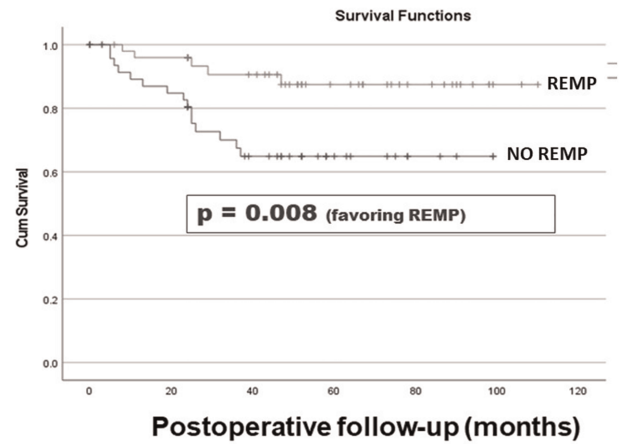


Figure 3. The survival curve for patients undergoing Bankart and remplissage or Bankart repair only comparing the time to recurrence of instability (dislocation or recurrent subluxation). REMP, Bankart repair with remplissage.

TABLE 2
Postoperative Recurrent Instability by Group^a

Group	Sex	Age at Time of Surgery, y	Time to Recurrent Instability, mos	Type of Recurrent Instability	Played Contact Sport	Hill-Sachs Width, cm	Hill-Sachs Lesion (%)	Treatment
REMP	M	26	8	Dislocation	N	1	20 ^b	Conservative
	M	17	11	Dislocation	N	1	12	Conservative
	M	24	25	Subluxations	N	2 ^b	14	Conservative
	M	28	29	Dislocation	N	2 ^b	25 ^b	Revision surgery
	M	22	47	Dislocation	Y	2 ^b	14	Pending surgery
NO REMP	M	24	5	Dislocation	N	2 ^b	11	Referred to a surgeon [moved away]
	M	30	5	Dislocation	N	0.7	25 ^b	Revision surgery
	M	18	6	Dislocation	Y	1.5	20 ^b	Revision surgery
	M	18	7	Dislocation	Y	2 ^b	10	Latarjet
	M	22	10	Dislocation	Y	2.3 ^b	11	Revision surgery
	M	26	13	Dislocation	Y	2 ^b	20	Revision surgery
	F	34	19	Dislocation	N	2 ^b	25 ^b	Referred to a surgeon [moved away]
	M	18	23	Dislocation	Y	1.5	20 ^b	Conservative
	M	30	24	Dislocation	Y	2.5 ^b	18 ^b	Revision surgery
	M	18	25	Subluxations	N	1.5	11	Conservative
	M	24	25	Subluxations	N	2 ^b	19 ^b	Conservative
	M	22	26	Subluxations	Y	1.0	17 ^b	Conservative
	M	20	32	Dislocations	N	1.5	16 ^b	Revision surgery
	M	41	36	Subluxations	N	1.5	12	Conservative
	M	22	37	Dislocation	Y	2 ^b	20 ^b	Revision surgery

^aF, female; M, male; REMP, Bankart repair with remplissage.

^bConsidered high risk to have recurrent instability based on a priori criteria.

DISCUSSION

The principal finding of this study was that the clinical benefits of arthroscopic Bankart repair with remplissage do not diminish with longer follow-ups. Our hypothesis that the significantly lower rate of recurrent instability seen in the REMP group at 2 years postoperative would

be sustained at a medium-term follow-up (mean of 4 years) was met. This finding was also observed in patients at high risk for reinjury based on Hill-Sachs size and contact sport. Patients undergoing arthroscopic Bankart repair without remplissage experienced failure (redislocated) earlier and had a higher rate of revision/reoperation than those who received a remplissage.

Bankart repair remains one of the most frequently utilized approaches in the surgical management of anterior glenohumeral instability. The present study findings, coupled with other recent literature, draw into question the efficacy of its use in isolation. Rollick et al²⁷ conducted a systematic review of 12 studies with a minimum 5-year follow-up. Arthroscopic Bankart repair resulted in a redislocation rate of 15.1% at a mean of 13 years postoperative and a recurrent rate of subjective instability of 20.2%—including subluxation, persistent apprehension, and subjective sense of instability. In a retrospective analysis of 271 patients who underwent arthroscopic Bankart repair, Zimmermann et al³⁶ found 28.4% recurrent instability, with 20% taking place >7 years postoperative. This led the authors to conclude that arthroscopic Bankart repair demonstrates decreasing effectiveness over time.³⁶ As the implications of bipolar bone loss become increasingly recognized, the indications for performing arthroscopic Bankart repair in isolation are limited.

The remplissage procedure was described in the literature in 2008 by Purchase et al²⁴ to address large humeral Hill-Sachs lesions in patients with anterior shoulder instability and subcritical glenoid bone loss. Remplissage stabilizes the joint through 2 mechanisms. The first is preventing engagement of the Hill-Sachs lesion on the glenoid rim, rendering the lesion extra-articular, and the second is acting as a posterior restraint, controlling excessive anterior translation of the humeral head.⁴ Consequently, the force acting on the repaired anterior capsule is decreased, and the risk of postoperative dislocation is reduced. The incorporation of remplissage at the time of arthroscopic Bankart repair has seen a rapid rise in popularity despite few level 1 studies evaluating its efficacy compared with Bankart repair alone. We previously reported findings from a double-blinded, randomized controlled trial comparing arthroscopic Bankart repair with and without remplissage in patients with traumatic recurrent anterior instability.²¹ All patients had a Hill-Sachs lesion and <15% glenoid bone loss. At a mean follow-up of 26.5 months, a significantly greater risk of postoperative recurrent instability was found in patients who did not have a remplissage procedure performed in conjunction with an arthroscopic Bankart repair. The rate of recurrent instability was 18% for Bankart alone and 4% for Bankart with remplissage. All episodes of recurrent instability were redislocations and were either self-reported or documented in a medical setting.

Similarly, in our medium-term follow-up study of the same cohort of patients, there was a significantly lower rate of recurrence favoring remplissage. When looking at failures (redislocation), our rates were 22% for Bankart and 8% for Bankart with remplissage, and these failures occurred earlier for the Bankart group versus Bankart with remplissage (16.5 and 23.8 months). When looking at overall postoperative recurrent instability, which included redislocation or ≥ 2 occurrences of subluxation, the rates were again lower in the REMP group versus the NO REMP group (10% and 30%, respectively). Overall, the extended follow-up period identified 3 patients in the REMP group and 6 patients in the NO REMP group who

experienced recurrent instability beyond the original study's 2-year endpoint.

Recurrence rates observed in the present study fall within the ranges documented in a 2019 systematic review¹ that included 6 nonrandomized studies comparing NO REMP to REMP. The mean follow-up intervals ranged from 12 to 66 months, and recurrence rates ranged from 0% to 20% for Bankart with remplissage versus 0% to 57% for Bankart alone.¹ Hurley et al¹⁶ published a meta-analysis in 2020 using 6 studies from the aforementioned systematic review plus 2 additional retrospective studies. As expected, there was a statistically significant difference in recurrence rates favoring arthroscopic Bankart repair with remplissage over isolated Bankart repairs. However, the pooled recurrence rates in both groups were on the lower end of the ranges reported in the systematic review (3.2% vs 16.8%, respectively; relative risk, 3.74; $P = .001$).¹⁶ The recurrence rates reported in this meta-analysis show less variability as the indications for soft tissue Bankart repair with or without remplissage evolve (eg, limited glenoid bone loss) and techniques improve. The present study reported recurrent instability rates at 4 years postoperative that fall within the range reported in this meta-analysis, slightly higher than the mean, which could be a function of the increased duration of follow-up.

As the present study focuses on medium-term data, the longest comparative study looking at isolated Bankart repair versus Bankart repair with remplissage shows a redislocation rate of 8% versus 0%, respectively, at a mean of 10 years postoperative.² This was a retrospective study involving a consecutive series of 79 patients diagnosed with recurrent anterior shoulder dislocation with or without a Hill-Sachs lesion. It is unclear how many patients did not have a Hill-Sachs lesion, but patients were excluded if they had an Instability Severity Index Score of >6 or evidence of glenoid bone loss on plain radiographs. Assessment of postoperative recurrence was made via telephone or in the clinic.

With respect to Bankart repair with remplissage, a systematic review revealed a pooled recurrence rate²⁰ of 4.7% with a mean follow-up of 32.5 months. In addition, there were 4 retrospective studies with longer-term endpoints that were not included in the systematic reviews. All 4 studies involve patients with engaging Hill-Sachs lesions and subcritical glenoid bone loss (<25%). Martinez-Catalan et al²² reported on 43 patients with a mean age of 29 years and a mean follow-up of 7.3 years (4-11 years). They reported that the rates of redislocation and revision surgery were 9.3% and 13.9%, respectively. The mean time to redislocation was 2.2 years (1.8-2.8 years). Bitar et al³ showed a recurrence rate of 9.5% in their series of 21 patients (mean age, 27.8 years) with a mean follow-up of approximately 7 years (range, 28-126 months). Cavalier et al⁷ divided patients in their study into minimal (<10%) or subcritical (10%-20%) glenoid bone loss. At a mean follow-up of 4 years (1-8.25 years), the rate of recurrent instability was 7.5%. All recurrence cases were associated with a traumatic event, with 50% of the episodes occurring >2 years postoperative. The authors noted that patients with 10% to 20% glenoid bone loss had a significantly

higher recurrence rate than those with minimal loss ($P = .001$). Considerable heterogeneity among studies likely explains the variability in postoperative recurrent instability rates. Differences include patient characteristics (age, sport, occupation, etc), methods used to assess and define recurrent instability (eg, redislocation vs resubluxation vs apprehension, or any combination of these), surgical techniques (eg, the number or location of anchors), and postoperative rehabilitation protocols. Another significant factor is the lack of uniformity when measuring and reporting humeral- and glenoid-sided bony defects.

With respect to patients who are at a greater risk of reinjury, of the 20 patients in our study who experienced overall recurrent instability, 9 were contact athletes and 17 were flagged as high risk based on the Hill-Sachs size; that is, having a Hill-Sachs lesion $\geq 15\%$ of the humeral head diameter or a width ≥ 2 cm.^{11,28} Our study offers evidence that Bankart repair with remplissage is superior to Bankart repair alone at reducing postoperative recurrence with a medium-term follow-up in both of these high-risk subsets. There is some debate as to whether bone block augmentation procedures (eg, Latarjet) are more appropriate in these high-risk cases. However, 3 recent systematic reviews suggest that bone block augmentation procedures and Bankart repair with remplissage are effective treatment options for recurrent anterior shoulder instability in patients with bipolar bone loss but subcritical glenoid bone loss. All have comparable functional outcomes, but given the fewer overall complications, remplissage may be safer.^{12,13,16} This theory is further supported by the Anterior Shoulder Instability International Consensus Group who in 2022 identified the primary indication for a remplissage procedure as “either an off-track or engaging Hill-Sachs lesion without severe glenoid bone loss” and that “unlike the bone-block procedure, complications after remplissage are rare, and loss of shoulder external rotation can be minimized...”¹⁴ Randomized controlled trials are needed to concretely define the circumstances in which a Bankart repair with remplissage should be abandoned in favor of bone block augmentation.²³

Additional surgery was seen in both study groups; however, the rate was notably higher in the NO REMP cohort, and this finding is consistent with the literature.¹⁴ The Latarjet procedure was the most frequent type of repeat surgery performed. This would be an expected choice in the patient with a failed soft tissue surgery. Although there is contentious debate on the optimal treatment for anterior glenohumeral instability with subcritical glenoid bone loss with an associated Hill-Sachs lesion, it is our preference to perform an arthroscopic soft tissue surgery (Bankart with remplissage) with Latarjet being reserved for revision cases. While Latarjet has consistently demonstrated a low rate of recurrent redislocation, the overall complication rate is 6% to 7%, as outlined by Hurley et al¹⁵ in a systematic review of 89 studies and 7175 patients, which is not insignificant. Furthermore, this rate has been reported²⁹ as high as 25%. In the present study, a single complication (2%) was reported, validating the safety profile of Bankart repair with remplissage.


This study does have some limitations. First, we relied on patient-reported outcomes only for instances of subluxation or dislocation. However, this methodology (phone interview) has been previously used to capture postoperative recurrence after shoulder stabilization surgery.^{2,17} Nevertheless, we could not evaluate the role of objective or subjective apprehension, which may have influenced the outcomes reported. No functional or radiographic assessments were conducted; thus, no comment on the progression of osteoarthritis or other pathologies was possible. Although contact versus noncontact sports were identified and reported, return to sports was not documented. Patients included in the present study did not all reach the same follow-up time point, thus introducing an element of outcome bias; that is, not all patients had reached the same time point in their recovery. Further, attrition or loss to follow-up may also have introduced a source of bias; nonetheless, there were no significant differences between the 2 groups. Participants may no longer have been blinded to their intervention. However, the assessor conducting the phone calls was unaware of group allocation. Study strengths include a randomized design, blinded surveyors, and standardized follow-up questions.

CONCLUSION

To treat traumatic recurrent anterior shoulder instability with a Hill-Sachs lesion and subcritical bone loss ($<15\%$), a significantly lower rate of overall postoperative recurrent instability was observed with arthroscopic Bankart repair and remplissage than with isolated Bankart repair at a medium-term follow-up (mean of 4 years). Patients who did not receive a remplissage experienced failure (redislocated) earlier and had a higher rate of revision/reoperation than those who received a concomitant remplissage.

ORCID iDs

Peter Lapner  <https://orcid.org/0000-0001-5393-2774>

Jonathon Marsh  <https://orcid.org/0000-0002-8399-6071>

REFERENCES

1. Alkaduhimi H, Verweij LPE, Willigenburg NW, van Deurzen DFP, van den Bekerom MPJ. Remplissage with Bankart repair in anterior shoulder instability: a systematic review of the clinical and cadaveric literature. *Arthroscopy*. 2019;35(4):1257-1266.
2. Bastard C, Herisson O, Gaillard J, Nourissat G. Impact of remplissage on global shoulder outcome: a long-term comparative study. *Arthroscopy*. 2019;35(5):1362-1367.
3. Bitar AC, Fabiani MC, Ferrari DG, et al. Clinical and functional outcomes of the remplissage technique to repair anterior shoulder dislocation: average 7 years of follow-up. *Musculoskelet Surg*. 2021; 105(1):61-67.
4. Boileau P, O'Shea K, Vargas P, Pinedo M, Old J, Zumstein M. Anatomical and functional results after arthroscopic Hill-Sachs remplissage. *J Bone Joint Surg Am*. 2012;94(7):618-626.
5. Brilakis E, Avramidis G, Malahias MA, et al. Long-term outcome of arthroscopic remplissage in addition to the classic Bankart repair for managing recurrent anterior shoulder instability with engaging

- Hill-Sachs lesions. *Knee Surg Sports Traumatol Arthrosc.* 2019;27(1):305-313.
6. Burkhart SS, De Beer JF. Traumatic glenohumeral bone defects and their relationship to failure of arthroscopic Bankart repairs: significance of the inverted-pear glenoid and the humeral engaging Hill-Sachs lesion. *Arthroscopy.* 2000;16(7):677-694.
 7. Cavalier M, Johnston TR, Tran L, Gauci MO, Boileau P. Glenoid erosion is a risk factor for recurrent instability after Hill-Sachs remplissage. *Bone Joint J.* 2021;103(4):718-724.
 8. Cicak N. Posterior dislocation of the shoulder. *J Bone Joint Surg Br.* 2004;86(3):324-332.
 9. Duey RE, Burkhart SS. Arthroscopic treatment of a reverse Hill-Sachs lesion. *Arthrosc Tech.* 2013;2(2):e155-e159.
 10. Giacomo GD, Itoi E, Burkhart SS. Evolving concept of bipolar bone loss and the Hill-Sachs lesion: from “engaging/non-engaging” lesion to “on-track/off-track” lesion. *Arthroscopy.* 2014;30(1):90-98.
 11. Giles JW, Elkinson I, Ferreira LM, et al. Moderate to large engaging Hill-Sachs defects: an in vitro biomechanical comparison of the remplissage procedure, allograft humeral head reconstruction, and partial resurfacing arthroplasty. *J Shoulder Elbow Surg.* 2012;21(9):1142-1151.
 12. Gouveia K, Abidi SK, Shamshoon S, et al. Arthroscopic Bankart repair with remplissage in comparison to bone block augmentation for anterior shoulder instability with bipolar bone loss: a systematic review. *Arthroscopy.* 2021;37(2):706-717.
 13. Haroun HK, Sobhy MH, Abdelrahman AA. Arthroscopic Bankart repair with remplissage versus Latarjet procedure for management of engaging Hill-Sachs lesions with subcritical glenoid bone loss in traumatic anterior shoulder instability: a systematic review and meta-analysis. *J Shoulder Elbow Surg.* 2020;29(10):2163-2174.
 14. Hurley ET, Matache BA, Wong I, et al; Anterior Shoulder Instability International Consensus Group. Anterior shoulder instability part I—diagnosis, nonoperative management, and Bankart repair—an international consensus statement. *Arthroscopy.* 2022;38(2):214-223.e7.
 15. Hurley ET, Schwartz LB, Mojica ES, et al. Short-term complications of the Latarjet procedure: a systematic review. *J Shoulder Elbow Surg.* 2021;30(7):1693-1699.
 16. Hurley ET, Toale JP, Davey MS, et al. Remplissage for anterior shoulder instability with Hill-Sachs lesions: a systematic review and meta-analysis. *J Shoulder Elbow Surg.* 2020;29(12):2487-2494.
 17. Inoue M, Tanaka S, Gotoh M, et al. Incidence of re-dislocation/instability after arthroscopic Bankart repair: analysis via telephone interviews. *Kurume Med J.* 2019;66(4):203-207.
 18. Jakobsen BW, Johannsen HV, Suder P, Søjbjerg JO. Primary repair versus conservative treatment of first-time traumatic anterior dislocation of the shoulder: a randomized study with 10-year follow-up. *Arthroscopy.* 2007;23(2):118-123.
 19. Kodali P, Jones MH, Polster J, Miniaci A, Fening SD. Accuracy of measurement of Hill-Sachs lesions with computed tomography. *J Shoulder Elbow Surg.* 2011;20(8):1328-1334.
 20. Liu JN, Gowd AK, Garcia GH, Cvetanovich GL, Cabarcas BC, Verma NN. Recurrence rate of instability after remplissage for treatment of traumatic anterior shoulder instability: a systematic review in treatment of subcritical glenoid bone loss. *Arthroscopy.* 2018;34(10):2894-2907.e2.
 21. MacDonald P, McRae S, Old J, et al. Arthroscopic Bankart repair with and without arthroscopic infraspinatus remplissage in anterior shoulder instability with a Hill-Sachs defect: a randomized controlled trial. *J Shoulder Elbow Surg.* 2021;30(6):1288-1298.
 22. Martinez-Catalan N, Kazum E, Zampeli F, Cartaya M, Cerlier A, Valenti P. Long-term outcomes of arthroscopic Bankart repair and Hill-Sachs remplissage for bipolar bone defects. *Eur J Orthop Surg Traumatol.* 2023;33(4):947-953.
 23. Prada C, Al-Mohrej OA, Patel A, Flood B, Leroux T, Khan M. Managing bone loss in shoulder instability—techniques and outcomes: a scoping review. *Curr Rev Musculoskelet Med.* 2021;14(6):447-461.
 24. Purchase RJ, Wolf EM, Hobgood ER, Pollock ME, Smalley CC. Hill-Sachs “remplissage”: an arthroscopic solution for the engaging Hill-Sachs lesion. *Arthroscopy.* 2008;24(6):723-726.
 25. Randelli P, Ragone V, Carminati S, Cabitza P. Risk factors for recurrence after Bankart repair a systematic review. *Knee Surg Sports Traumatol Arthrosc.* 2012;20(11):2129-2138.
 26. Robinson CM, Howes J, Murdoch H, Will E, Graham C. Functional outcome and risk of recurrent instability after primary traumatic anterior shoulder dislocation in young patients. *J Bone Joint Surg Am.* 2006;88(11):2326-2336.
 27. Rollick NC, Ono Y, Kurji HM, et al. Long-term outcomes of the Bankart and Latarjet repairs: a systematic review. *Open Access J Sports Med.* 2017;8:97-105.
 28. Sekiya JK, Wickwire AC, Stehle JH, Debski RE. Hill-Sachs defects and repair using osteoarticular allograft transplantation: biomechanical analysis using a joint compression model. *Am J Sports Med.* 2009;37(12):2459-2466.
 29. Shah AA, Butler RB, Romanowski J, Goel D, Karadagli D, Warner JJP. Short-term complications of the Latarjet procedure. *J Bone Joint Surg Am.* 2012;94(6):495-501.
 30. Sugaya H, Moriishi J, Dohi M, Kon Y, Tsuchiya A. Glenoid rim morphology in recurrent anterior glenohumeral instability. *J Bone Joint Surg Am.* 2003;85(5):878-884.
 31. Thomazeau H, Langlais T, Hardy A, et al. Long-term, prospective, multicenter study of isolated Bankart repair for a patient selection method based on the Instability Severity Index Score. *Am J Sports Med.* 2019;47(5):1057-1061.
 32. Widjaja AB, Tran A, Bailey M, Proper S. Correlation between Bankart and Hill-Sachs lesions in anterior shoulder dislocation. *ANZ J Surg.* 2006;76(6):436-438.
 33. Wolf EM, Arianjam A. Hill-Sachs remplissage, an arthroscopic solution for the engaging Hill-Sachs lesion: 2- to 10-year follow-up and incidence of recurrence. *J Shoulder Elbow Surg.* 2014;23(6):814-820.
 34. Yamamoto N, Itoi E, Abe H, et al. Contact between the glenoid and the humeral head in abduction, external rotation, and horizontal extension: a new concept of glenoid track. *J Shoulder Elbow Surg.* 2007;16(5):649-656.
 35. Yiannakopoulos CK, Mataragas E, Antonogiannakis E. A comparison of the spectrum of intra-articular lesions in acute and chronic anterior shoulder instability. *Arthroscopy.* 2007;23(9):985-990.
 36. Zimmermann SM, Scheyerer MJ, Farshad M, Catanzaro S, Rahm S, Gerber C. Long-term restoration of anterior shoulder stability: a retrospective analysis of arthroscopic Bankart repair versus open Latarjet procedure. *J Bone Joint Surg Am.* 2016;98(23):1954-1961.